

## Plasma pentraxin-3 level in acute appendicitis

Pentraxin 3 levels in acute appendicitis

Ayetullah Temiz<sup>1</sup>, Yavuz Albayrak<sup>2</sup>, Konca Altınkaynak<sup>3</sup>, Adem Aslan<sup>4</sup>, Yılmaz Özdemir<sup>5</sup><sup>1</sup>Department of General Surgery, Erzurum Regional Training and Research Hospital, Erzurum,<sup>2</sup>Department of General Surgery, Atatürk University School Of Medicine, Erzurum,<sup>3</sup>Department of Biochemistry, Erzurum Regional Training and Research Hospital, Erzurum,<sup>4</sup>Department of General Surgery, İstanbul Sultan Abdülhamid Han Sample Training and research Hospital, İstanbul,<sup>5</sup>Department of Gastroenterology Surgery, Erzurum Regional Training and Research Hospital, Erzurum, Turkey

## Abstract

Aim: In recent years, it has been found that plasma levels of Pentraxin-3 (PTX3) are elevated in systemic inflammatory conditions. In this study, we aimed to demonstrate the diagnostic value of PTX3 in patients with Acute Appendicitis (AA). Material and Method: This study was carried out in the general surgery clinic of Erzurum Regional Training and Research Hospital between 1st December 2015 and 31st March 2016 and included 56 patients who were diagnosed with acute appendicitis and 28 healthy controls. Results: In a comparison of the groups, mean PTX3 level in control group was  $3.08 \pm 1.49$  ng/mL, whereas in acute suppurative appendicitis or perforated appendicitis it was  $7.96 \pm 4.29$  ng/mL, indicating a significant between-group difference ( $P < 0.0001$ ). PTX3 level differed significantly between the control group and acute suppurative appendicitis and between the control group and perforated appendicitis ( $P < 0.0001$ ). However, there was no significant difference in the PTX3 levels between acute suppurative appendicitis and perforated appendicitis ( $P > 0.05$ ). The area under the ROC curve (AUC) for the diagnosis of acute appendicitis using PTX3 was 0.883. Discussion: PTX3 may be a potential new marker for the diagnosis of acute appendicitis because the PTX3 level is significantly higher in patients with AA.

## Keywords

Acute Appendicitis; Pentraxin- 3; Inflammation

DOI: 10.4328/ACAM.6088 Received: 16.11.2018 Accepted: 15.12.2018 Published Online: 21.12.2018 Printed: 01.11.2019 Ann Clin Anal Med 2019;10(6): 666-70  
Corresponding Author: Ayetullah Temiz, Department of General Surgery, Erzurum Area Training and Research Hospital, 25100, Erzurum, Turkey.  
T.: +90 4422325248 E-Mail: temiz-49@hotmail.com  
ORCID ID: <https://orcid.org/0000-0003-2178-3369>

Introduction:

Acute appendicitis (AA) is the most common surgical disease affecting approximately 7 % of the population that can present at any time throughout life and at all ages [1,2]. AA is usually diagnosed by a combination of physical examination findings such as a clinical information from patients, conventional biomarkers likewhite blood cell count (WBC), mean platelet volume (MPV), absolute neutrophil count (ANC) and C-reactive protein (CRP); and imaging methods such as ultrasound imaging and computed tomography [3-6]. Clinical diagnosis of AA is often difficult even for experienced surgeons, and the rate of negative explorations can approach 20–30% [7,8]. Delays in the diagnosis of AA can cause perforation and other complications. Therefore, there is a need for simple and economic novel laboratory methods for diagnosis of AA.

Pentraxin 3 (PTX3) is a member of the pentraxin family and is also called the tumor necrosis factor-inducible protein that is located on gene 14 (TSGF 14) [9]. PTX3 is secreted by macrophages and various other cells when induced by primary inflammatory mediators such as tumor necrosis factor alpha, interleukin-1, and lipopolysaccharide [10]. Plasma levels of PTX3 are very low (2 ng/mL). In recent years, it has been found that plasma levels of PTX3 are elevated in systemic inflammatory conditions. In this study, we aimed to investigate the diagnostic value of PTX3 in patients with AA.

Material and Method

This study was carried out in the general surgery clinic of Erzurum Regional Training and Research Hospital between 1st December 2015 and 31st March 2016 and included 56 patients who were diagnosed with acute appendicitis and 28 healthy controls. Study subjects were classified into four subgroups for analysis.

1. Group 1 (control; n = 28): A control group was selected from healthy individuals who visited the hospital for routine health check-up in the Infectious Diseases Clinics and did not fulfill any of the exclusion criteria.
2. Group 2: There were 31 patients who underwent pathologic examination and were diagnosed with acute suppurative appendicitis.
3. Group 3: There were 25 patients diagnosed, clinically and pathologically, with perforated appendicitis.
4. Group 4: There were 56 patients with acute suppurative appendicitis or perforated appendicitis.

Inclusion and exclusion criteria

All patients who underwent surgery for appendicitis on the basis of history, physical findings and relevant clinical data were eligible for study inclusion. Postoperatively, the resected appendix was sent for histopathological examination. Cases, where the histopathology was not consistent with appendicitis, were excluded from the study. Exclusion criteria included heart failure, peripheral vascular disease, hematological disorders, acute or chronic infection, cancer, prior antibiotic therapy, age <10 years, pregnancy, hepatic diseases, and other known inflammatory conditions. None of the patients had received prior anticoagulants, nonsteroidal anti-inflammatory drugs, or oral contraceptives.

Biochemical Analysis

Blood samples collected into EDTA tubes from all participants were centrifuged at 4000 rpm for 10 min at 4°C. The obtained

plasma samples were stored in a deep freezer at –80°C until analysis. Levels of PTX3 in plasma samples were measured by the enzyme-linked immunosorbent assay (ELISA) method using the Human Pentraxin 3 ELISA Kit (Abcam, UK) according to the manufacturer’s instruction, and the assay was analyzed on a Bio-Tek Power Wave ST microplate spectrophotometer (USA).

Statistical Analysis

All data analyses were conducted with SPSS 16.0 for Windows, and results are presented as mean ± standard deviation (SD). For continuous variables, the independent samples test was used to analyze variance among groups. P-values less than 0.05 were considered statistically significant. Plasma PTX3 (ng/mL) values are given as mean ± SD for normal dispersion. We applied the unpaired t-test for 2-group comparison, ANOVA for multi-group comparisons, Tukey’s test for subgroup analysis in homogeneous groups, and Tamhane’s test when homogeneous distribution was not observed. A receiver operating characteristics (ROC) curve was plotted to demonstrate the diagnostic value of PTX3 in acute appendicitis. A written informed consent from the patients was waived because the present study was performed prospectively.

Results

Characteristics of the study subjects, including patient age and levels of WBC, CRP, and PTX3, are shown in Table 1. Of the 56 patients who underwent appendectomies, 30 were male and 26 female; in the control group, 6 subjects were male and 22 female. There was a significant difference between WBC counts of the patient and control groups (P <0.0001), but no difference between the group of subjects with perforated appendicitis and that of subjects with suppurative appendicitis (P>0.05). WBC distribution of the patient and control groups is shown in Figure 1. In a comparison of the 2 groups, mean PTX3 level in Group 1 was 3.08 ± 1.49 ng/mL, whereas in Group 4 it was 7.96 ± 4.29 ng/mL, indicating a significant between-group difference (P<0.0001). PTX3 level differed significantly between Group 1 and Group 2 and between Group 1 and Group 3 (P <0.0001). However, there was no significant difference in the PTX3 levels between Group 2 and Group 3 (P>0.05). The distribution of PTX3 levels of the patient and control groups are shown in Figure 2. The area under the ROC curve (AUC) for the diagnosis of acute appendicitis using PTX3 is shown in Figure 3.

Discussion

Pentraxins are a family of multimeric proteins divided into short and long pentraxins, based on their primary structure; CRP is the prototype of the short pentraxin subfamily, and PTX3 is a prototypic long pentraxin. [11]. PTX3 is an inflammatory me-

Table 1. Age, Plasma pentraxin 3, white blood cells and C-reactive protein in patients and control subjects

	Groups			
	Control subjects (Group I), n:28	Acute suppurative appendicitis (Group II), n :31	Acute perforated appendicitis (Group III), n: 25	Acute suppurative and perforated appendicitis (Group IV), n: 56
Age (Year)	34.0±10.7	35.7±17.1	33.8±16.1	34.8±16.6
WBC, (x10 <sup>9</sup> /L)	7397±1135	13067±4633	14712±4926	13801±4794
CRP, (mg/dl)	0,66±1.12	3.12±4.43	3.78±6.14	3.41±5.22
Pentraxin (ng/ml)	3.08±1.49	7.91±4.55	8.03±4.04	7.96±4.29

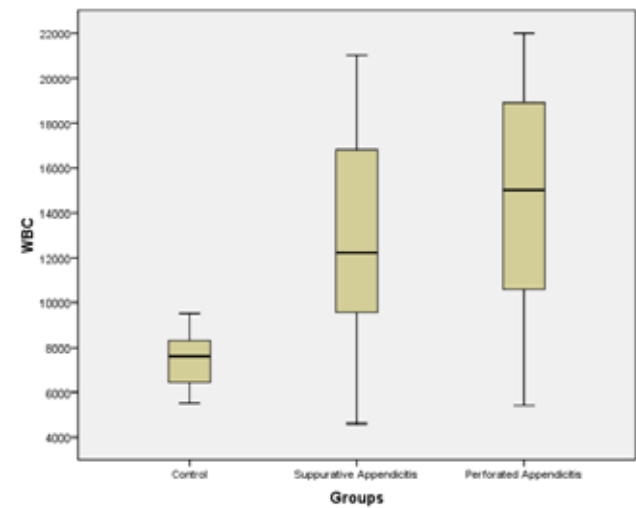


Figure 1. Absolute white blood cell (WBC) counts by category of groups. WBC X 106/L, Acute suppurative appendicitis: A. Suppurative app, Acute perforated appendicitis: A.perforated app.

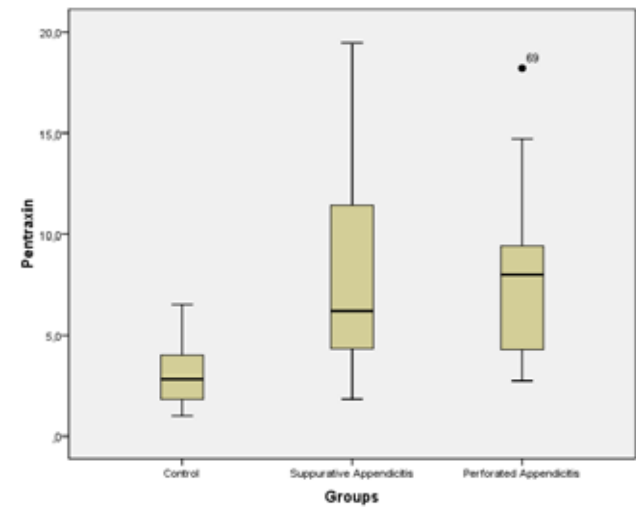


Figure 2. Pentraxin 3 counts by category of groups. (Pentraxin 3 ng/mL. Suppurative app.: Acute suppurative appendicitis, A. Perforated app.: Acute perforated appendicitis).

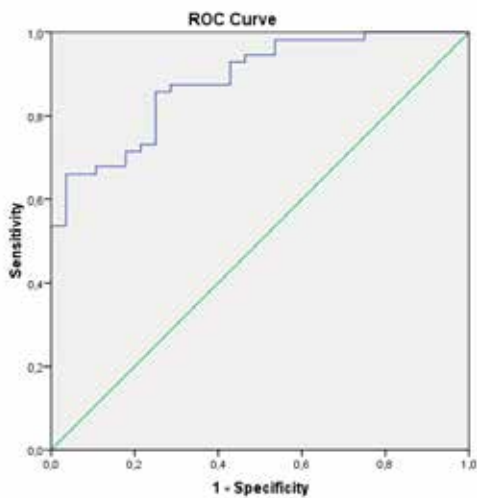


Figure 3. Receiver operating characteristic (ROC) curve of pentraxin 3.

diator secreted from mononuclear phagocytes, dendritic cells, fibroblasts and endothelial cells within the long pentraxin family [12]. PTX3 is found in human serum and plasma, urine [13], cerebrospinal fluid [14], pleura [15], amniotic fluid [16] and in

synovial fluid [17]. Although plasma levels of PTX3 are very low (2 ng/mL) normally, these dramatically and rapidly increase to 200–800 ng/mL in 6–8 hours in the pathological state [18]. Elevated PTX3 levels have been reported in many types of cardiovascular diseases including acute coronary syndrome, congestive heart failure and heart failure with normal ejection fraction [19–21]. In addition, recent reports have shown that PTX3 may have potential to be used as a vascular inflammatory marker to differentiate the activity of Takayasu aortitis [22,23]. Previous clinical trials have shown that PTX3 levels increased in tumors such as liposarcoma, glioma, lung and prostate cancers, or benign hyperplasia when compared to healthy humans [24–27]. In a study of patients with pancreatic cancer, elevated levels of pentraxin were associated with worse prognosis [28]. It has been detected that PTX3 levels increased in systemic immune diseases such as systemic inflammatory response syndrome (SIRS), rheumatoid arthritis, progressive systemic sclerosis, Chug–Strauss syndrome, Wegener’s granulomatosis and microscopic polyangiitis [17, 29–32]. Moreover, PTX3 levels increase in chronic renal failure [33,34]. Therefore, it was of interest to determine PTX3 expression patterns in inflammatory bowel diseases such as Crohn’s disease and ulcerative colitis. As IL-6 was found to have increased expression in active Crohn’s disease, but not in ulcerative colitis, it is not surprising that plasma PTX3 levels were found to be increased only in patients with ulcerative colitis (because IL-1, but not IL-6, induces PTX3 expression). Therefore, PTX3 can be used as a marker of exacerbation in people with inflammatory bowel disease [35,36]. PTX3 levels rise rapidly in response to inflammation and infection, whereas PTX3 concentration is less than 2 ng/mL in healthy individuals [37,38]. Mauri et al. [39] conducted a study showing that elevated PTX3 level is useful as a predictive factor of severe sepsis and death. PTX3 can be evaluated in patients with a suspected infection on admission, and may be used to predict many variables indicating severe sepsis i.e. need for ICU stay, hypotension, acute renal insufficiency and need for mechanical ventilation in the emergency room setting. Thus, PTX3 may help to stratify patients to ensure effective resource utilization [40]. In a previous study, PTX3 level peaked within the first hour of admission to the hospital and was found to be an early indicator of shock in severe meningococcal disease [41]. Elevated plasma PTX3 concentrations are also present in a variety of inflammatory conditions. High PTX3 levels are important for determining the severity of Dengue virus infection, leptospirosis and epidemic nephropathic disease [42–44]. Aksungur et al. [45] reported that PTX3 levels were high in patients with cholecystitis, especially in patients with gangrenous cholecystitis. In our study, PTX3 levels were elevated both in patients with acute suppurative appendicitis and perforated appendicitis, without any significant between-group difference. PTX3 may be a potential new marker for the diagnosis of acute appendicitis. In our study, we found that PTX3 levels were significantly elevated in patients with acute appendicitis compared with the control group. The AUC value of PTX3 was found to be highly elevated, up to 0.883, in the ROC curve for sensitivity and specificity in the diagnosis of acute appendicitis. Therefore, the value of PTX3 in the diagnosis of acute appendicitis may be considered to be high.

Worldwide, AA is the most common surgical pathology. Negative surgical explorations are undertaken from time to time for misdiagnosis. There is a need for additional laboratory tests to support a diagnosis of AA and to reduce negative explorations.

Therefore, negative explorations, unnecessary investigations and invasive procedures can be reduced through an increase in the number of tests and methods that will improve a specific diagnosis of AA. Because the PTX3 level is significantly higher in patients with AA, PTX3 can be used as a supporting marker of AA.

### Scientific Responsibility Statement

*The authors declare that they are responsible for the article's scientific content including study design, data collection, analysis and interpretation, writing, some of the main line, or all of the preparation and scientific review of the contents and approval of the final version of the article.*

### Animal and human rights statement

*All procedures performed in this study were in accordance with the ethical standards of the institutional and/or national research committee and with the 1964 Helsinki declaration and its later amendments or comparable ethical standards. No animal or human studies were carried out by the authors for this article.*

**Funding:** None

### Conflict of interest

*None of the authors received any type of financial support that could be considered potential conflict of interest regarding the manuscript or its submission.*

### References

- Hardin DM Jr. Acute appendicitis: review and update. *Am Fam Phys.* 1999; 60: 2027-34.
- Blewett JC, Krummel TM. Perforated appendicitis: past and future controversies. *Semin Pediatr Surg.* 1995; 4: 234-8.
- Smink DS, Finkelstein JA, Garcia Penã BM, Shannon MW, Taylor GA, Fishman SJ. Diagnosis of acute appendicitis in children using a clinical practice guideline. *J Pediatr Surg.* 2004; 39: 458-63.
- Kharbanda AB, Taylor GA, Fishman SJ, Bachur RGA. Clinical Decision Rule to Identify Children at Low Risk for Appendicitis. *Pediatrics.* 2005; 116: 709-16.
- Mikaëlsson C, Ambjörnsson E. The value of C-reactive protein (CRP) determinations in patients with suspected acute appendicitis. *Ann Chir Gynaecol.* 1984; 73: 281-4.
- Albayrak Y, Albayrak A, Albayrak F, Yıldırım R, Ayulu B, Uyanık A, et al. Mean Platelet Volume: A New Predictor in Confirming Acute Appendicitis Diagnosis. *Clin Appl Thromb Hemost.* 2011; 17(4): 362-6.
- Andersson RE, Hugander A, Thulin AJ. Diagnostic accuracy and perforation rate in appendicitis: association with age and sex of the patient and with appendicectomy rate. *Eur J Surg.* 1992; 158(1): 37-41.
- Yang HR, Wang YC, Chung PK, Chen WK, Jeng LB, Chen RJ. Laboratory tests in patients with acute appendicitis. *ANZ J Surg.* 2006; 76(1-2): 71-4.
- Emsley J, White HE, O'Hara BP, Oliva G, Srinivasan N, Tickle IJ, et al. Structure of pentameric human serum amyloid P component. *Nature.* 1994; 367: 338-45.
- Introna M, Alles VV, Castellano M, Picardi G, De Gioia L, Bottazzai B, et al. Cloning of mouse ptx3, a new member of the pentraxin gene family expressed at extra hepatic sites. *Blood.* 1996; 87: 1862-72.
- Assandri R, Monari M, Colombo A, Dossi A, Montanelli A. Pentraxin3 Plasma Levels and Disease Activity in Systemic Lupus Erythematosus. *Autoimmune Dis.* 2015; 2015 DOI: 10.1155/2015/354014.
- Bottazzi B, Doni A, Garlanda C, Mantovani A. An integrated view of humoral innate immunity: pentraxins as a paradigm. *Annu Rev Immunol.* 2010; 28: 157-83.
- Ge W, Wang HL, Sun RP. Pentraxin 3 as a novel early biomarker for the prediction of Henoch-Schönlein purpura nephritis in children. *European Journal of Pediatrics.* 2014; 173(2): 213-8.
- Zanier ER, Brandi G, Peri G, Longhi L, Zoerle T, Tettamanzi M, et al. Cerebrospinal fluid pentraxin 3 early after subarachnoid hemorrhage is associated with vasospasm. *Intensive Care Medicine.* 2011; 37: 302-9.
- Yeo CD, Kim JW, Cho MR, Kang JY, Kim SJ, Kim YK, et al. Pleural fluid pentraxin-3 for the differential diagnosis of pleural effusions. *Tuberculosis and Respiratory Diseases.* 2013; 75: 244-9.
- Cruciani L, Romero R, Vaisbuchetal E. Pentraxin 3 in amniotic fluid: a novel association with intra amniotic infection and inflammation. *Journal of Perinatal Medicine.* 2010; 38: 161-71.
- Luchetti MM, Piccinini G, Mantovani A, Peri G, Matteucci C, Pomponio G, et al. Expression and production of the long pentraxin PTX3 in rheumatoid arthritis (RA). *Clinical&Experimental Immunology.* 2000; 119: 196-202.
- Muller B, Peri G, Doni A, Torri V, Landmann R, Bottazzi B, et al. Circulating levels of the long pentraxin PTX3 correlate with severity of infection in critically ill patients. *Crit Care Med.* 2001; 29: 1404-7.
- Peri G, Introna M, Corradi D, Iacuitti G, Signorini S, Avanzini F, et al. PTX3, a prototypal long pentraxin, is an early indicator of acute myocardial infarction in humans. *Circulation.* 2000; 102: 636-41.
- Suzuki S, Takeishi Y, Niizeki T, Koyama Y, Kitahara T, Sasaki T, et al. Pentraxin 3, a new marker for vascular inflammation, predicts adverse clinical outcomes in patients with heart failure. *AmHeart J.* 2008; 155: 75-81.
- Matsubara J, Sugiyama S, Nozaki T, Sugamura K, Konishi M, Ohba K, et al. Pentraxin 3 is a new inflammatory marker correlated with left ventricular diastolic dysfunction and heart failure with normal ejection fraction. *J Am Coll Cardiol.* 2011; 57: 861-9.
- Ishihara T, Haraguchi G, Kamiishi T, Tezuka D, Inagaki H, Isobe M. Sensitive assessment of activity of takayasu's arteritis by pentraxin3, a new biomarker. *J Am Coll Cardiol.* 2011; 57: 1712-13.
- Dagna L, Salvo F, Tiraboschi M, Bozzolo EP, Franchini S, Doglioni C, et al. Pentraxin-3 as a marker of disease activity in takayasu arteritis. *Ann Intern Med.* 2011; 155: 425-33.
- Willeke F, Assad A, Findeisen P, Schromm E, Grobholz R, von Gerstenbergk B, et al. Over expression of a member of the pentraxin family (PTX3) in human soft tissue liposarcoma. *European journal of cancer.* 2006; 42(15): 2639-46.
- Locatelli M, Ferrero S, Martinelli Boneschi F, Biocchi L, Zavanone M, Maria Gaini S, et al. The long pentraxin PTX3 as a correlate of cancer-related inflammation and prognosis of malignancy in gliomas. *Journal of neuro immunology.* 2013; 260(1-2): 99-106.
- Stallone G, Cormio L, Netti GS, Infante B, Selvaggio O, Fino GD, et al. Pentraxin 3: a novel biomarker for predicting progression from prostatic inflammation to prostate cancer. *Cancer research.* 2014; 74 (16): 4230-8.
- Diamandis EP, Goodglick L, Planque C, Thornquist MD. Pentraxin-3 is a novel biomarker of lung carcinoma. *Clinical cancer research: an official journal of the American Association for Cancer Research.* 2011; 17(8): 2395-9.
- Kondo SI, Ueno H, Hosoi H, Hashimoto J, Morizane C, Koizumi F, et al. Clinical impact of pentraxin family expression on prognosis of pancreatic carcinoma. *British Journal of Cancer.* 2013; 109: 739-46.
- Mauri T, Coppadoro A, Bellani G, bombino M, Peri G, Mantovani A, et al. Pentraxin 3 in acute respiratory distress syndrome: an early marker of severity. *Critical Care Medicine.* 2008; 36: 2302-308.
- Iwata Y, Yoshizaki A, Ogawa F, Komura K, Hara T, Muroi E, et al. Increased serum pentraxin 3 in patients with systemic sclerosis. *Journal of Rheumatology.* 2009; 36: 976-83.
- Fazzini F, Peri G, Doni A, Dell'Antonio G, Cin ED, Bozzolo E, et al. PTX3 in small-vessel vasculitides: an independent indicator of disease activity produced at sites of inflammation. *Arthritis and Rheumatism.* 2001; 44: 2841-50.
- Mauri T, Bellani G, Coppadoro A, Peri G, Cuccovillo I, Cugno M, et al. Persisting high levels of plasma pentraxin 3 over the first days after severe sepsis and septic shock associated with mortality. *Intensive Care Medicine.* 2010; 36: 621-9.
- Yilmaz MI, Sonmez A, Ortiz A, Sağlam M, Kılıç S, Eyleten T, et al. Soluble TWEAK and PTX3 in non dialysis CKD patients: impact on endothelial dysfunction and cardiovascular outcomes. *Clinical Journal of the American Society of Nephrology.* 2011; 6: 785-92.
- Tong M, Carrero JJ, Qureshi AR, Anderstam B, Heimbürger O, Barany P, et al. Plasma pentraxin 3 in patients with chronic kidney disease: associations with renal function, protein-energy wasting, cardiovascular disease, and mortality. *Clinical Journal of the American Society of Nephrology.* 2007; 2: 889-97.
- Kato S, Ochiai M, Sakurada T, Ohno S, Miamoto K, Sagara M, et al. Increased expression of long pentraxin PTX3 in inflammatory bowel diseases. *Digestive Diseases and Sciences.* 2008; 53: 1910-16.
- Savchenko AS, Inoue A, Ohashi R, Jiang S, Hasegawa G, Tanaka T, et al. Long pentraxin 3 (PTX3) expression and release by neutrophils in vitro and in ulcerative colitis. *Pathology International.* 2011; 61: 290-7.
- Bottazzi B, Garlanda C, Cotena A, Moalli F, Jaillon S, Deban L, et al. The long pentraxin PTX3 as a prototypic humoral pattern recognition receptor: interplay with cellular innate immunity. *Immunol Rev.* 2009; 227: 9-18.
- Yamasaki K, Kurimura M, Kasai T, Sagara M, Kodama T, Inoue K, et al. Determination of physiological plasma pentraxin 3 (PTX3) levels in healthy populations. *Clin Chem Lab Med.* 2009; 47: 471-77.
- Mauri T, Bellani G, Patroniti N, Coppadoro A, Peri G, Cuccovillo I, et al. Persisting high levels of plasma pentraxin 3 over the first days after severe sepsis and septic shock associated with mortality. *Intensive Care Med.* 2010; 36: 621-9.
- Uusitalo-Seppälä R, Huttunen R, Aittoniemi J, Koskinen P, Leino A, Vahlberg T, Rintala EM. Pentraxin 3 (PTX3) associated with severe sepsis and fatal disease in emergency room patients with suspected infection: a prospective cohort study. *PLoSOne.* 2013; 8(1). DOI: 10.1371/journal.pone.0053661.
- Sprong T, Peri G, Neeleman C, Mantovani A, Signorini S, van der Meer JWM, et al. Pentraxin 3 and C-reactive protein in severe meningococcal disease. *Shock.* 2009; 31: 28-32.

42. Mairuhu AT, Peri G, Setiati TE, Hack CE, Koraka P, Soemantri A, et al. Elevated plasma levels of the long pentraxin, pentraxin 3, in severe dengue virus infections. *J Med Virol*. 2005; 76: 547–52.
43. Wagenaar JF, Goris MG, Gasem MH, Isbandrio B, Moalli F, Mantovani A, et al. Long pentraxin PTX3 is associated with mortality and disease severity in severe Leptospirosis. *J Infect*. 2009; 58: 425–32.
44. Outinen TK, Makela S, Huhtala H, Hurme M, Meri S, Pörsti I, et al. High pentraxin-3 plasma level associate with thrombocytopenia in acute Puumalahanta virus-induced nephropathia epidemica. *Eur J Clin Microbiol Infect Dis*. 2011; 31: 957–63.
45. Aksungur N, Özoğul B, Öztürk G, Arslan Ş, Karadeniz E, Korkut E, et al. Prognostic importance of penteraxin 3 levels in acute cholesistits. *Ulus Travma Acil Cerrahi Derg*. 2015; 21(5): 380-4.

**How to cite this article:**

**Temiz A, Albayrak Y, Altınkaynak K, Aslan A, Özdemir Y. Plasma pentraxin-3 level in acute appendicitis. *Ann Clin Anal Med* 2019;10(6): 666-70.**